


Name: Balwinder Kumar |  | Legal Name: Balwinder Kumar

# IR BIOPSY

Collected on November 25, 2022 1:19 PM

If you have questions or concerns regarding your test results, contact the clinician who ordered the test. 

## Results

### Impression

#### IMPRESSION:

1. Successful ultrasound-guided biopsy of gallbladder mass. 5 18-gauge ultrasound-guided core biopsies were obtained.

Electronically Signed by: 

### Narrative

PROCEDURE: IR BIOPSY, 11/25/2022 10:51 AM

COMPARISON: CT, 11/24/2022

CLINICAL INDICATION: Gallbladder mass.

#### PROCEDURE:

1. Ultrasound-guided biopsy gallbladder mass
2. Moderate sedation

OPERATOR: Sasaki

#### TECHNIQUE:

Preliminary sonographic imaging of the abdomen was performed demonstrating large mass involving the gallbladder. CT scan also obtained which confirms findings of a large mass surrounding the gallbladder.. The abdomen was prepped and draped in usual sterile fashion. Lidocaine was used for local anesthesia. Using direct ultrasound visualization, a 17-gauge guide needle was advanced into the lesion via a gallbladder may. Then, 5 core biopsies were obtained of the gallbladder mass with an 18-gauge needle. Images along the needle track following biopsy needle removal show no evidence for bleeding at the liver surface. The skin site was cleaned, and a sterile bandage dressing placed. The patient tolerated the procedure well without complication.

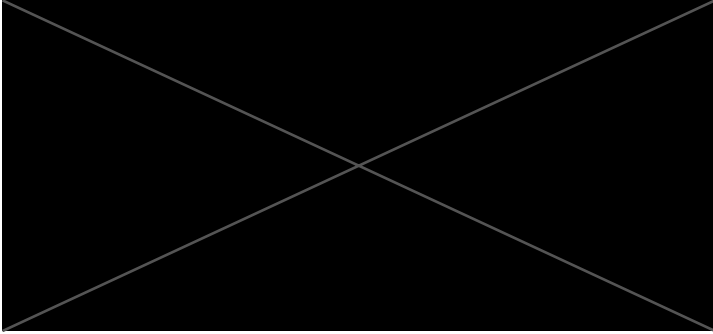


**MEDICATIONS:**

Versed 4 mg IV, Fentanyl 50 mcg IV, Zofran 4 mg IV. Moderate sedation was used for this procedure with continuous cardiopulmonary monitoring by a registered nurse, physician performing the procedure supervised the conscious sedation throughout the entire procedure. Sedation time of 28 minute.

**COMPLICATIONS:**

None



MyChart® licensed from Epic Systems Corporation© 1999 - 2025