


Name: Balwinder Kumar |

| Legal Name: Balwinder Kumar

CT Abdomen Pelvis With Contrast

Collected on December 24, 2022 2:06 AM

If you have questions or concerns regarding your test results, contact the clinician who ordered the test. 

Results

Impression

IMPRESSION:

1. Status post resection of the gallbladder, gallbladder mass, right colon, and a portion of the liver adjacent to the gallbladder fossa.
2. A fluid collection in the gallbladder fossa measures 4.4 x 4.9 x 1.9 cm. There is a small focus of gas within the collection. Abscess is not excluded, although there is no clear rim enhancement or organization at this time.
3. Question of wall thickening of the gastric antrum/pylorus, nonspecific.
4. Small hiatal hernia.
5. Small gastrohepatic, periportal, and retroperitoneal lymph nodes.

Electronically Signed by:  12/24/2022 2:24 AM

Narrative

PROCEDURE: CT ABDOMEN PELVIS W CONTRAST, 12/24/2022 1:46 AM

COMPARISON: 12/6/2022

CLINICAL INDICATION: Fever. Status post laparotomy, cholecystectomy, colectomy, and partial liver resection, and blood transfusion. Partial omentectomy

TECHNIQUE:

Postcontrast helical CT acquisition performed from the top the diaphragms thru the pubic rami with coronal and sagittal reformats.

IV Contrast: 100 cc Omnipaque 300 nonionic iodinated contrast.

PO Contrast: None.

Complications: None.

Total Exam Dose Length Product: 386.57 mGy-cm

Total Exam CT Dose Index volume: 8.36 mGy

FINDINGS:

Visualized lung bases: Limited evaluation of the visualized lung bases demonstrates scarring in the posteromedial aspect of the right lung base. There is no consolidation, pleural, or pericardial effusion.

Liver: No focal lesion is identified. There has been interval partial resection of the liver along the gallbladder fossa. There is no intra- or extrahepatic biliary ductal dilatation. The hepatic and portal veins are patent.

Gallbladder: Status post cholecystectomy and resection of gallbladder mass. There is a fluid collection in the gallbladder fossa measuring approximately 4.4 x 1.9 x 4.9 cm. There is a small focus of gas within the collection. There is no definite rim enhancement of the collection. There is a small gastrohepatic lymph node adjacent to the gallbladder fossa, measuring approximately 7 mm.

Pancreas: No focal masses are identified. There is no pancreatic ductal dilatation. There are no significant peripancreatic inflammatory changes.

Spleen: No splenomegaly or focal abnormalities.

Adrenal glands: Unremarkable.

Kidneys and collecting system: There is no hydronephrosis or nephrolithiasis. No discrete masses are identified. The kidneys enhance symmetrically.

Bowel: There is a small hiatal hernia. There is question of wall thickening of the gastric antrum/pylorus, nonspecific. Status post right hemicolectomy with anastomosis. There is no evidence for bowel obstruction. There are no significant inflammatory changes associated with the bowel loops. There is no free intraabdominal fluid or air.

Pelvis: The urinary bladder, uterus, and adnexa are grossly unremarkable.

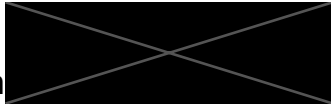Miscellaneous: There are small retroperitoneal, gastrohepatic, and periportal lymph nodes. There is mild atherosclerotic calcification of the abdominal aorta.

Visualized osseous structures: There are no suspicious lesions in the visualized bones. No acute fractures or subluxation identified. There is mild to moderate multilevel spondylosis of the spine. There is moderate to severe facet arthropathy in the lower lumbar spine.



 Scan 1

Ordering provider:



Reading physician:

Study date: December 24, 2022 2:24 AM

Collection date: December 24, 2022 2:06 AM

Result date: December 24, 2022 2:24 AM

Result status: Final

MyChart® licensed from Epic Systems Corporation© 1999 - 2025

